Acc# 274783

DP-MS-77-89

RECORDS ADMINISTRATION
R0060593

Ultrastructure of "Red Sore" Lesions on Largemouth Bass (*Micropterus salmoides*): The Association of the Peritrich *Epistylis* and the Bacterium *Aeromonas hydrophila*

by

T. C. Hazen, M. L. Raker, and G. W. Esch

Department of Biology
Wake Forest University
Winston-Salem, North Carolina 27109

C. B. Fliermans

Savannah River Laboratory
E. I. du Pont de Nemours and Company
Aiken, South Carolina 29801

SRL
RECORD COPY

A paper proposed for publication in *Protozoology*.

The information contained in this article was developed during the course of work under Contract No. E-(38-1)-900 between Wake Forest University, Winston-Salem, N.C., and the United States Department of Energy (DOE) and under Contract No. AT(07-2)-1 between DOE and E. I. du Pont de Nemours and Co.

This document was prepared in conjunction with work accomplished under Contract No. DE-AC09-76SR00001 with the U.S. Department of Energy.

DISCLAIMER

This report was prepared as an account of work sponsored by an agency of the United States Government. Neither the United States Government nor any agency thereof, nor any of their employees, makes any warranty, express or implied, or assumes any legal liability or responsibility for the accuracy, completeness, or usefulness of any information, apparatus, product or process disclosed, or represents that its use would not infringe privately owned rights. Reference herein to any specific commercial product, process or service by trade name, trademark, manufacturer, or otherwise does not necessarily constitute or imply its endorsement, recommendation, or favoring by the United States Government or any agency thereof. The views and opinions of authors expressed herein do not necessarily state or reflect those of the United States Government or any agency thereof.

This report has been reproduced directly from the best available copy.

Available for sale to the public, in paper, from: U.S. Department of Commerce, National Technical Information Service, 5285 Port Royal Road, Springfield, VA 22161, phone: (800) 553-6847, fax: (703) 605-6900, email: orders@ntis.fedworld.gov online ordering: http://www.ntis.gov/ordering.htm

Available electronically at http://www.doe.gov/bridge

Available for a processing fee to U.S. Department of Energy and its contractors, in paper, from: U.S. Department of Energy, Office of Scientific and Technical Information, P.O. Box 62, Oak Ridge, TN 37831-0062, phone: (865) 576-8401, fax: (865) 576-5728, email: reports@adonis.osti.gov

DP-MS-77-89

Ultrastructure of "Red Sore" Lesions on Largemouth Bass (*Micropterus salmoides*): The Association of the Peritrich *Epistylis* and the Bacterium *Aeromonas hydrophila*

by

T. C. Hazen, M. L. Raker, and G. W. Esch

Department of Biology
Wake Forest University
Winston-Salem, North Carolina 27109

C. B. Fliermans

Savannah River Laboratory
E. I. du Pont de Nemours and Company
Aiken, South Carolina 29801

SYNOPSIS

Red sore disease is a common malady of fish in the southeastern United States and is believed to be caused primarily by the peritrich ciliate *Epistylis* sp. *Aeromonas hydrophila* is believed to be the secondary agent of the disease. However, electron microscope and bacteriological studies of red sore lesions from largemouth bass (*Micropterus salmoides*) revealed that *Aeromonas hydrophila* and not *Epistylis* sp. is the primary cause of the disease. These studies also revealed that *Epistylis* sp. attaches benignly to fish; *A. hydrophila* adheres to the stalks of *Epistylis* sp.; *A. hydrophila* occurs in 96% of the lesions examined, and only 35% of the lesions have *Epistylis* sp.; *Epistylis* sp. stalks do not have a structure indicative of lytic enzyme

production; and *A. hydrophila* clumps are associated with perforations in fish epithelia.

INTRODUCTION

In the southeastern United States, the gram negative bacterium *Aeromonas hydrophila* appears to be intimately associated with the peritrich ciliate *Epistylis* sp. in causing a pathology known as "red sore" disease. This disease is common among centrarchid fishes in the southeast, and may reach epizootic proportions, resulting in massive fish kills (9, 10). Dean (2) reported that in excess of 34,000 fish had died of the disease in Badin Lake, North Carolina, in 1973.

The external pathology is manifested as scale erosion and hemorrhea of the pitlike lesions. These lesions may cover 75% of the body surface of a largemouth bass *(Micropterus salmoides)* and ultimately produce hemorrhagic septicemia and death. Studies by Esch *et al.* (3) showed a correlation between thermal loading and a striking seasonal periodicity in infected fish in Par Pond, a reservoir near Aiken, South Carolina. They also showed a significant relationship between the body condition of the fish and the likelihood of being infected with red sore disease.

The primary invader in red sore disease is thought to be the stalked, colonial ciliate *Epistylis* sp. (10). Rogers (10) has suggested that the stalk of *Epistylis* sp. produces an enzyme that causes scale erosion, allowing a secondary invasion by the gram negative bacterium *A. hydrophila*. Other researchers (7)

maintain that the stalk does not produce any lytic enzymes, making *Epistylis* sp. incapable of causing the hemorrhaging lesion that is considered typical of the disease. Although *A. hydrophila* and *Epistylis* sp. appear to be closely associated in the red sore phenomenon, the exact nature of their juxtaposition to each other and to the host, *Micropterus salmoides*, is unresolved. In this study, transmission and scanning electron microscopy were used to examine the nature of these relationships.

Materials and Methods

Fish were collected by a combination of electrofishing and angling at Par Pond, Aiken, South Carolina (3). Immediately upon capture, the fish were examined for lesions, weighed, and measured. If lesions were found, they were excised and fixed.

For scanning electron microscope studies, lesions were fixed with 4% glutaraldehyde in 0.1M Sorensen's phosphate buffer (pH 7.5) for 8 hr at 4°C. The specimens were then washed in 0.1M Sorensen's phosphate buffer (pH 7.5) (8), dehydrated in an ethanol series (50, 70, 80, 95 and 100%), and dried by using a Bomar SPC-900 (Tacoma, WA) critical point dryer with CO_2 as a solvent. All specimens were coated with a film of 400 nm of gold-palladium alloy with a Technic Incorporated (Alexandria, VA.) Hummer II sputtering system. Specimens were then viewed with a Super Mini-Sem (ISI) scanning electron microscope at accelerating voltages from 10 to 25 kV. Records were made with Polaroid 55 P/N film.

For transmission electron microscope studies, lesions were fixed with 4% glutaraldehyde in 0.1M sodium cacodylate buffer (pH 7.5) for 2 hr at 4°C. The specimens were then washed in 0.1M sodium cacodylate buffer (pH 7.5) and postfixed for 1 hr at room temperature with 2% osmium tetroxide in 0.1M sodium cacodylate (pH 7.5). The specimens were then rinsed in 0.2M sodium cacodylate buffer (pH 7.5) and dehydrated in an ethanol series (50, 70, 80, 95, and 100%). Dehydrated specimens were infiltrated with propylene oxide and embedded in an Epon-Araldite plastic mixture. Embedded specimens were sectioned with a Porter Blum MT2-B ultramicrotome and double-stained with 3% uranyl acetate followed by 0.2% lead citrate (13). Stained sections were examined with a Zeiss EM9S-2 transmission electron microscope with an accelerating voltage of 60 kV. Records were made with Kodak 4899 electron microscope film.

One hundred and fourteen external body lesions on largemouth bass *(Micropterus salmoides)* were examined for the presence of *Epistylis* sp. and *A. hydrophila*. Scrapings of lesions were fixed in phosphate buffered formalin, stained with Semichon's acetic-carmine stain, and examined for *Epistylis* sp. according to the methods of Hazen *et al.* (5). These same lesions were also swabbed with sterile loops which were then streaked on Rimler-Shotts (R-S) medium (11). The R-S medium plates were incubated at 35°C for 20 hr and then examined for yellow colonies, which are 95% presumptive *A. hydrophila* (11). Colonies were selected and subjected

to further verification as *A. hydrophila* by using API 20 strips (Analtab, Inc.). Isolates also were tested for antibiotic sensitivity patterns, oxidase production, and gram stain reaction.

Specific anti-*A. hydrophila* fluorescent antibody was prepared by using isolates identified as *A. hydrophila* by our laboratories and from an American Type Culture Collection isolate (No. 7966). These fluorescent antibodies and impression slides were stained and prepared according to the procedure of Fliermans *et al.* (4).

RESULTS

Stained scrapings of bass lesions revealed that 96% (110/114) of these lesions contained *A. hydrophila* which could be cultured. Only 35% (40/114) of the same lesions were infected with *Epistylis* sp. The quantities of *A. hydrophila* cultured from the lesions also indicated that there were large numbers of viable bacteria in these hemorrhaging areas. Bacteriological swabs from uninfected areas of diseased fish as well as healthy fish demonstrated that less than 1% of the cultures were positive for *A. hydrophila*. Impression slides of the lesions stained with anti-*A. hydrophila* fluorescent antibody (Hazen, *et al.*, unpublished results) further substantiated that *A. hydrophila* is indeed found in great numbers in lesions and is not just a spurious contaminant.

Scanning electron micrographs revealed large numbers of rod-shaped bacteria surrounding and closely adhering to the stalk of *Epistylis* sp. (Figs. 1 and 2). Transmission electron micrographs

of stalk cross sections (Fig. 3) and longitudinal sections (Fig. 4) revealed how closely the bacteria were attached. The results of the culture and staining studies confirmed that these bacteria were *A. hydrophila*. Bacteria were never found on the zooid of *Epistylis* sp. They were found only on the stalk (Fig. 5), even when a stalk and a zooid were in very close juxtaposition (Fig. 6). Bacteria were, however, found among the oral ciliature (Fig. 7) which is not so surprising since *Epistylis* sp. is a bacteriovore. Rod-shaped bacteria were also in lesions that did not include any *Epistylis* sp. (Fig. 8). However, the density of bacteria in these areas was reduced compared with that in lesions containing *Epistylis* sp. (Figs. 9 and 10).

Epistylis sp. attached to the surface of the fish did not appear to cause any pathology. At no time was the stalk of *Epistylis* sp. observed to penetrate the host membrane. The attachment appeared as a spreading of stalk fibers over the substrate (Fig. 11). These striated stalk fibers (myonemes) can be seen in cross and longitudinal sections in Figs. 3 and 4. This type of attachment was observed on both soft (epithelia) and hard (scales) fish substrates (Figs. 11 and 12). Close examination of the *Epistylis* sp's. attachment revealed no penetration or pitting of fish tissue (Figs. 11, 12, and 13). The rod-shaped bacteria, however, were found to be associated with perforations in the tissue (Fig. 14). Sections of the stalk revealed only stalk fibers and a few scattered mitochondria; no Golgi bodies or other organelles could be identified (Figs. 3 and 4).

DISCUSSION

The intimate association between *A. hydrophila* and the stalk of *Epistylis* sp. cannot be readily explained. The stalk has been reported to exude a mucilaginous material (7), and this substance may act as either a nutrient source for the bacteria or may have adherence qualities lacking on other nearby surfaces. Both cross and longitudinal sections of *Epistylis* sp. stalks covered with bacteria reveal electron diffuse material, which may represent a mucous coat.

A. hydrophila was found in 96% of the red sore lesions examined while only 35% of these lesions included *Epistylis* sp. Other studies have shown that high densities of *A. hydrophila* alone can experimentally induce lesions in bass (Hazen and Esch, unpublished data); *Epistylis* sp. alone will not produce hemorrhaging lesions (7). If *Epistylis* sp. caused the lesions, its points of attachment would be likely sites for pathology. Micrographs revealed what appears to be a benign relationship with bass epithelia. Like Lom (7), we too did not observe *Epistylis* sp. to penetrate host cell membranes. However, bacteria were closely associated with perforations in bass epithelia. Other studies on largemouth bass infected with red sore disease reveal an internal pathology that is similar to that caused by a bacterium (Huizinga, in preparation).

Contrary to the conclusions of Rogers (10), our results indicate that the etiological agent of red sore disease is not

Epistylis sp. but rather the gram negative bacterium *A. hydrophila*. *A. hydrophila* may be the primary invader that causes a lesion that the *Epistylis* sp. secondarily invades as an ectocommensal. Alternatively, a teletroch of *Epistylis* sp. may attach benignly to a fish and then develop into a colony which is subsequently colonized by *A. hydrophila*. Once the density of *A. hydrophila* has increased sufficiently upon the stalks, the bacteria could then produce enough lytic enzyme to cause a lesion. *A. hydrophila* is known to produce a number of lytic enzymes (12, 6, 1) while *Epistylis* sp., on the other hand, is said to be incapable of producing lytic toxins (7). Sections of the stalk did not reveal any organelles capable of producing enzymes and the scarcity of mitochondria further suggests an inactive role for the stalk.

The frequency of occurrence of *A. hydrophila* in lesions without *Epistylis* sp. and our observations that *A. hydrophila* alone can induce lesions in fish held in aquaria indicate that *A. hydrophila* is most likely the primary cause of red sore lesions on largemouth bass.

ACKNOWLEDGMENTS

The information contained in this article was developed during the course of work under Contract No. E-(38-1)-900 between Wake Forest University, Winston-Salem, N.C., and the United States Department of Energy (DOE) and under Contract No. AT(07-2)-1 between DOE and E. I. du Pont de Nemours and Co.

REFERENCES

1. Bernheimer AW and Avigad LS. 1974. Partial characterization of aerolysin, a lytic exotoxin from Aeromonas hydrophila. Infect. Immun. 9, 1016-21.

2. Dean J. 1974. Fish disease outbreak. Wild. N. Carol. 38, 18-9.

3. Esch GW, Hazen TC, Dimock RV Jr., and Gibbons JW. 1976. Thermal effluent and the epizootiology of the ciliate Epistylis and the bacterium Aeromonas in association with centrarchid fish. Trans. Am. Micros. Soc. 95, 687-93.

4. Fliermans CB, Bohlool BB, and Schmidt EL. 1974. Autoecological study of the chemoautotroph, Nitrobacter, by immunofluorescence. Appl. Microbiol. 27, 124-29.

5. Hazen TC, Smith G, and Dimock RV Jr. 1976. A method for fixing and staining peritrich ciliates. Trans. Am. Micros. Soc. 95, 693-5.

6. Liu PV. 1961. Observations on the specificities of extracellular antigens of the genera Aeromonas and Serratia. J. Gen. Microbiol. 24, 145-53.

7. Lom J. 1973. The mode of attachment and relation to the host in Apiosoma piscicola (Blanchand) and Epistylis lwoffi (Faure-Fremiet), ectocommensals of freshwater fish. Folia Parasitol. 20, 105-12.

8. McClean RC and Cook WRI. 1952. Plant Science Formulae. Macmillan and Co. Ltd., London, England, 205pp.

9. Miller RM and Chapman WR. 1976. Epistylis and Aeromonas hydrophila infections in fishes from North Carolina reservoirs. Prog. Fish-Cult. 38, 165-8.

10. Rogers WA. 1971. Disease in fish due to the protozoan Epistylis (ciliata:peritricha) in the southeastern U.S. Proc. 25th Conf. Southeastern Association of Game and Fish Commissioners.

11. Shotts EB and Rimler R. 1973. Medium for the isolation of Aeromonas hydrophila. Appl. Microbiol. 26, 550-3.

12. Wretlind BR, Mollby R, and Wadstrom T. 1971. Separation of two hemolysins from Aeromonas hydrophila by isoelectric focusing. Infec. Immun. 4, 503-5.

13. Veneable JH and Coggeshall R. 1965. A simplified lead citrate stain for use in electron microscopy. J. Cell Biol. 25, 407.

LEGEND

Figs. 1 and 2. Stalks of Epistylis sp. covered with rod-shaped bacteria (B), × 20,000.

Fig. 3. Stalk of Epistylis sp. in cross section showing bacteria (B) surrounding stalk and striated stalk fibers (SS), × 4,000.

Fig. 4. Stalk of Epistylis sp. in longitudinal section showing bacteria (B) surrounding stalk and striated stalk fibers (SS), × 3,400.

Fig. 5. Epistylis sp. oral ciliature and zooid surface (Z), × 3,040.

Fig. 6. Section of Epistylis sp. zooid (Z) and stalk (S) showing bacteria (B) on stalk but not on zooid, × 4,600.

Fig. 7. Bacteria (B) among Epistylis sp. oral ciliature, cilia (C), × 5,000.

Fig. 8. Largemouth bass epithelia within a lesion showing bacteria (B) and red blood cells (R), × 2,280.

Fig. 9. Higher magnification showing packing of rod-shaped bacteria, × 15,000.

Fig. 10. Surface of largemouth bass lesion near stalks (S) of Epistylis sp. showing accumulations of rod-shaped bacteria (B), × 1,500.

Figs. 11 and 12. Attachment point of Epistylis sp. stalk on scale (Sc) Fig. 11 and epithelia Fig. 12, × 2,300.

Fig. 13. Attachment of Epistylis sp. to a largemouth bass scale, × 1,000.

Fig. 14. Bacteria associated with perforation of largemouth bass epithelia, × 6,000.

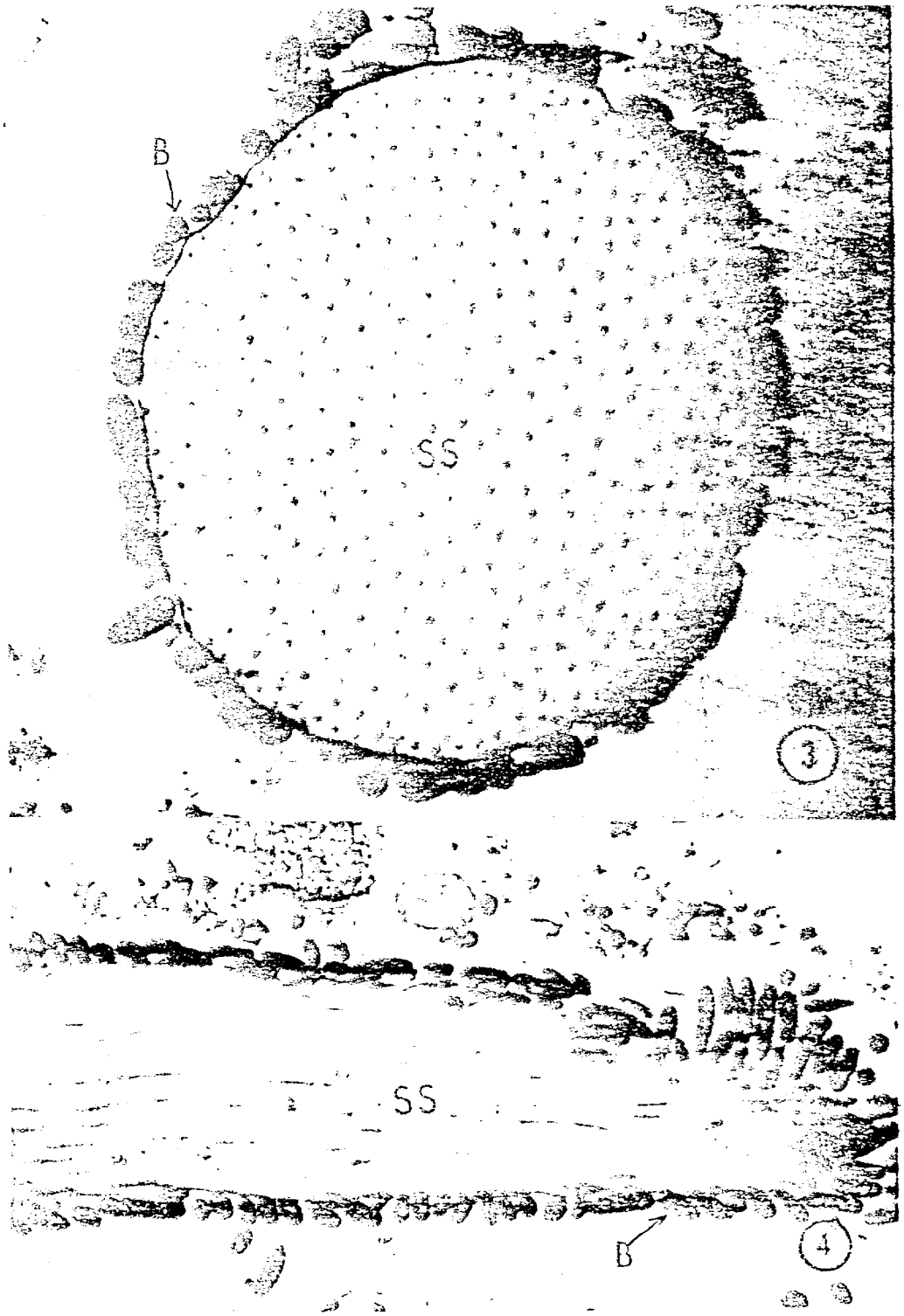
B
SS
3
SS
B
4

6



7


S
S
S
B
S